

Technical Note

The “Bony Bankart Bridge” Procedure: A New Arthroscopic Technique for Reduction and Internal Fixation of a Bony Bankart Lesion

Peter J. Millett, M.D., M.Sc., and Sepp Braun, M.D.

Abstract: Arthroscopic treatment of bony Bankart lesions can be challenging. We present a new easy and reproducible technique for arthroscopic reduction and suture anchor fixation of bony Bankart fragments. A suture anchor is placed medially to the fracture on the glenoid neck, and its sutures are passed around the bony fragment through the soft tissue including the inferior glenohumeral ligament complex. The sutures of this anchor are loaded in a second anchor that is placed on the glenoid face. This creates a nontilting 2-point fixation that compresses the fragment into its bed. By use of the standard technique, additional suture anchors are used superiorly and inferiorly to the bony Bankart piece to repair the labrum and shift the joint capsule. We call this the “bony Bankart bridge” procedure. **Key Words:** Arthroscopy—Bony Bankart lesion—Suture bridge—Instability—Shoulder.

A vulsion fractures of the anterior glenoid rim, so-called bony Bankart lesions, are associated with anteroinferior glenohumeral instability.^{1,2} These fractures typically occur when the glenohumeral joint dislocates. The incidence ranges from 4% to 70% in the literature, with an increased prevalence in male patients.³ Because these fractures can easily be missed on plain radiographs, computed tomography scans are an important means for correct diagnosis and estimation of the size of the fragment.^{4,5}

Early surgical treatment of acute injuries is recommended for better outcomes.³ Arthroscopic techniques

can be used to address bony Bankart lesions. The techniques that have been described include the Bankart repair technique with suture anchors placed at the glenoid rim⁶ with or without additional sutures for augmentation passed around or through the fragment.⁷ In case of larger fragments, fixation with cannulated screws can be used.⁸ There are some limitations with these techniques. For example, the suture anchor technique does not provide compression of the fracture fragment, and the bony piece may tilt because of the single point of fixation. When trying to penetrate the fragment to pass a suture, the fragment may split. Placing cannulated screws can be very challenging technically and can also result in splitting of the bony fragment.

Most recently, techniques for arthroscopic internal reduction and fixation of greater tuberosity fractures with double-row or suture-bridge techniques have been described.⁹⁻¹¹

We present an arthroscopic technique to fixate and compress the bony fragment that is based on the same principles of 2-point fixation and compression. The procedure is reproducible and can provide for stable, reliable fixation of the fragment.

From the Steadman Hawkins Clinic (P.J.M.) and Steadman Hawkins Research Foundation (S.B.), Vail, Colorado, U.S.A.

S.B. is currently a research fellow sponsored by Arthrex, Naples, Florida. P.J.M. has financial interests in Arthrex. There was no financial support for this study.

Address correspondence and reprint requests to Peter J. Millett, M.D., M.Sc., Steadman Hawkins Clinic, Suite 1000, 181 W Meadow Dr, Vail, CO 81657, U.S.A. E-mail: drmillett@steadman-hawkins.com

© 2009 by the Arthroscopy Association of North America

0749-8063/09/2501-8277\$36.00/0

doi:10.1016/j.arthro.2008.07.005

TECHNIQUE

The patient is placed in the beach-chair position with the index arm in a pneumatic arm holder (Spider; Tenet Medical Engineering, Calgary, Alberta, Canada). After an examination under anesthesia to assess the grade of instability, a standard posterior portal for arthroscopy is established. The diagnostic arthroscopy evaluates all aspects of the glenohumeral joint to ensure all pathologies will be diagnosed.

A high anterosuperior portal is established with a 5.0-mm cannula (Arthrex, Naples, FL) in the rotator interval, and the bony Bankart lesion is assessed with a probe. Subsequently, an accessory anteroinferior portal is established, entering the joint just superior to the subscapularis tendon. An 8.25-mm cannula (Arthrex) is used in this portal to assist with suture management. A 70° arthroscope is used to visualize the neck of the glenoid, medial to the fracture. Typically, the labrum and inferior glenohumeral ligament (IGHL) complex are attached to the bony fragment. These attachments should be preserved. Instruments are placed through both anterior portals to mobilize the bony Bankart and the entire IGHL as a sleeve of continuous tissue, inferiorly to the 6-o'clock position. The glenoid neck and the fractured surface of the bony fragment are prepared by use of an elevator and a shaver to create bleeding surfaces to enhance bone-to-bone healing.

An elevator is introduced from the anterosuperior

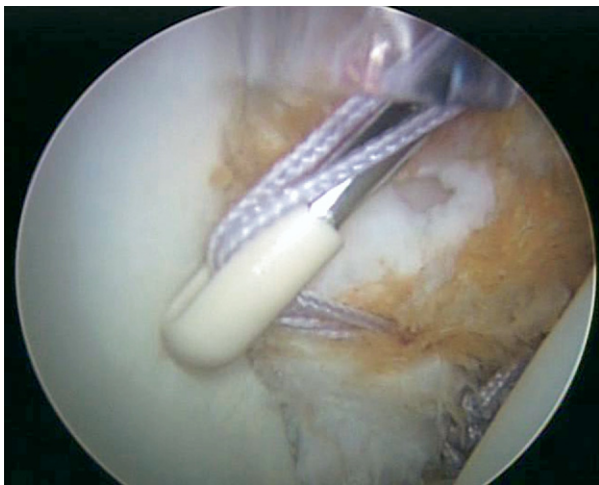


FIGURE 1. Arthroscopic view of a left shoulder from posterior standard portal. The anchor on the glenoid face is placed through a cannula in a standard anterosuperior portal to reduce the bony Bankart piece. The anchor is loaded with the 2 suture limbs of the anchor, which had been placed medially to the fragment on the glenoid neck previously.

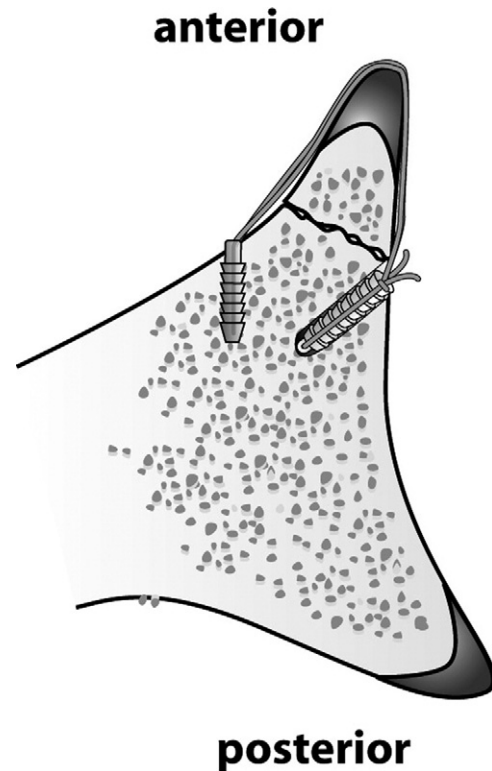


FIGURE 2. Cross-section: anchor position relative to fracture.

portal to lift the bony fracture piece off the glenoid neck so that the first anchor can be placed medially on the glenoid neck. This will form the medial fixation point for the Bankart bridge. Depending on the size of the fragment, 1 or 2 anchors can be used. If 1 anchor is to be used, it is placed medial (axial plane) to the donor site on the glenoid neck and in the midportion (sagittal plane) of the fracture. A 3.0-mm Bio-SutureTak anchor (Arthrex) loaded with FiberWire (Arthrex) is used. Both limbs of the suture are passed through the soft tissues, medial to the bony piece, by use of a shuttling technique with a 45° curved SutureLasso (Arthrex). The sutures are then parked outside the anteroinferior cannula.

The next step is to place a suture anchor inferior to the bony fracture piece on the glenoid rim. This anchor will secure the labrum and IGHL complex, inferior to the bony fragment. As for a typical arthroscopic repair, the medial suture limb is passed through the IGHL complex, shifting the IGHL complex and labrum superiorly and medially tightening the axillary pouch. Pulling the tissue superiorly and medially from the anterosuperior portal with a grasper, before securing the knot, helps control the size of the shift. The

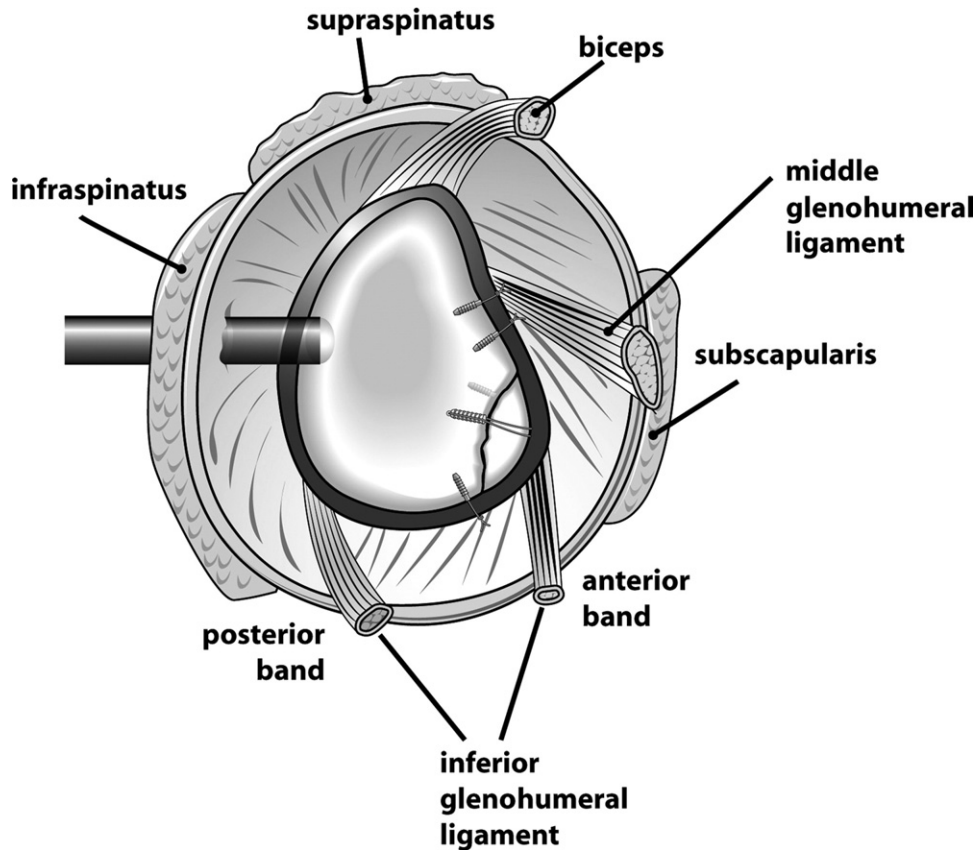


FIGURE 3. Final repair with reduced bony Bankart piece, repaired labrum, and shifted capsule and IGHL complex.

sutures are then tied by use of a sliding-locking Weston knot that is backed up with 2 alternating half-hitches. The free limbs are cut. Typically, 1 anchor is placed inferior to the bony fragment; however, depending on the size of the bony piece and its position on the glenoid face, 2 inferior anchors may be used on occasion.

The bony Bankart is now fixed with a bridging technique. The sutures will span the bony fragment and provide 2-point fixation of the fragment. The sutures from the medial anchor are retrieved out the anteroinferior cannula, and the tension can be assessed to test the fracture reduction and to evaluate the optimal position for the lateral fixation anchor on the glenoid face before drilling. The drill hole should be placed on the glenoid face at the cartilage-fracture margin. The 2 free limbs of the medial suture anchor are fed into a 3.5-mm Bio-PushLock anchor (Arthrex), which is then pushed into the drill hole on the glenoid face (Fig 1). The suture limbs are tensioned before final fixation of the anchor. By these means, the bony fragment is reduced and compressed back into its

donor bed, and an arthroscopic osteosynthesis is achieved (Fig 2). This “bony Bankart bridge” provides secure 2-point fixation and compression of the fracture, without tilting of the bony piece. The security of the construct can be tested with a probe. The free limbs are cut flush with the Bio-PushLock anchor.

Additional repair of the superior capsule, labrum, and middle glenohumeral ligament should then be performed superior to the Bankart bridge. We recommend placing at least 1 anchor superior to the Bankart bridge because this will provide additional rotational stability. Depending on the size of the bony Bankart lesion, 1 or more bony Bankart bridges can be used to secure the fragment. Figure 3 illustrates the final repair.

DISCUSSION

In acute cases or when radiographic and arthroscopic assessment show a mobile bony Bankart fragment, the technique presented can be used to treat these lesions arthroscopically. In cases of older frac-

tures or bone loss with fragments that cannot be reduced or when there has been resorption of the bone fragment, other techniques such as an open or arthroscopic Latarjet procedure or iliac crest bone graft reconstruction should be considered.¹²⁻¹⁵

The bony Bankart bridge technique can restore the glenoid cavity by reducing the Bankart fracture under direct visual control while at the same time restoring tension in the IGHL complex. The anchors placed superior and inferior to the Bankart bridge provide additional rotational control, whereas the Bankart bridge itself compresses the fracture down onto the glenoid with 2-point fixation, creating a large surface area for bony healing. Compression and rotational stability comprise the main difference between our technique and previously published arthroscopic techniques with 1-point fixation.⁶ Our technique uses the same principles as recently published techniques for arthroscopic approaches to fractures of the greater tuberosity.⁹⁻¹¹ Thus the described technique combines the advantages of the arthroscopic Bankart repair with its ability to selectively shift the capsule and repair the labrum while at the same time restoring the bony anatomy with stable, compressing, nontilting fracture fixation. The bony Bankart bridge technique is reproducible and easy to perform and is an excellent way of arthroscopically treating bony Bankart lesions.

REFERENCES

1. Bigliani LU, Newton PM, Steinmann SP, Connor PM, McIlveen SJ. Glenoid rim lesions associated with recurrent anterior dislocation of the shoulder. *Am J Sports Med* 1998;26:41-45.
2. Bankart AS, Cantab MC. Recurrent or habitual dislocation of the shoulder-joint. 1923. *Clin Orthop Relat Res* 1993;3-6.
3. Porcellini G, Paladini P, Campi F, Paganelli M. Long-term outcome of acute versus chronic bony Bankart lesions managed arthroscopically. *Am J Sports Med* 2007;35:2067-2072.
4. Chuang TY, Adams CR, Burkhart SS. Use of preoperative three-dimensional computed tomography to quantify glenoid bone loss in shoulder instability. *Arthroscopy* 2008;24:376-382.
5. Griffith JF, Antonio GE, Tong CW, Ming CK. Anterior shoulder dislocation: Quantification of glenoid bone loss with CT. *AJR Am J Roentgenol* 2003;180:1423-1430.
6. Porcellini G, Campi F, Paladini P. Arthroscopic approach to acute bony Bankart lesion. *Arthroscopy* 2002;18:764-769.
7. Sugaya H, Kon Y, Tsuchiya A. Arthroscopic repair of glenoid fractures using suture anchors. *Arthroscopy* 2005;21:635.e1-635.e5. Available online at www.arthroscopyjournal.org.
8. Cameron SE. Arthroscopic reduction and internal fixation of an anterior glenoid fracture. *Arthroscopy* 1998;14:743-746.
9. Ji JH, Kim WY, Ra KH. Arthroscopic double-row suture anchor fixation of minimally displaced greater tuberosity fractures. *Arthroscopy* 2007;23:1133.e1-1133.e4. Available online at www.arthroscopyjournal.org.
10. Kim KC, Rhee KJ, Shin HD, Kim YM. Arthroscopic fixation for displaced greater tuberosity fracture using the suture-bridge technique. *Arthroscopy* 2008;24:120.e1-120.e3. Available online at www.arthroscopyjournal.org.
11. Song HS, Williams GR. Arthroscopic reduction and fixation with suture-bridge technique for displaced or comminuted greater tuberosity fractures. *Arthroscopy* 2008;24:956-960.
12. Lafosse L, Lejeune E, Bouchard A, Kakuda C, Gobezie R, Kochhar T. The arthroscopic Latarjet procedure for the treatment of anterior shoulder instability. *Arthroscopy* 2007;23:1242.e1-1242.e5. Available online at www.arthroscopyjournal.org.
13. Latarjet M. Technic of coracoid preglenoid arthroereisis in the treatment of recurrent dislocation of the shoulder. *Lyon Chir* 1958;54:604-607 (in French).
14. Warner JJ, Gill TJ, O'Hollerhan JD, Pathare N, Millett PJ. Anatomical glenoid reconstruction for recurrent anterior glenohumeral instability with glenoid deficiency using an autogenous tricortical iliac crest bone graft. *Am J Sports Med* 2006;34:205-212.
15. Millett PJ, Clavert P, Warner JJ. Open operative treatment for anterior shoulder instability: When and why? *J Bone Joint Surg Am* 2005;87:419-432.